

Outcome of Total Hip Arthroplasty in Northern Iran: A Prospective Study

GHAFFAR HABIBI SHEKARDASHT¹, NASSER JANMOHAMMADI², MASOUD SHAYESTEH AZAR³, MOHAMMAD HOSSEIN KARIMI NASAB⁴, SEYED MOKHTAR ESMAEILNEZHAD GANJI⁵, MOHAMMAD ZAMANI⁶

ABSTRACT

Introduction: Total Hip Arthroplasty (THA) is one of the most frequent major surgical procedures in orthopedics.

Aim: To audit the results of THA in Babol, Northern Iran.

Materials and Methods: From 2014 to 2015, all patients with indication for THA referred to Shahid Beheshti and Rohani teaching hospitals in Babol were recruited in this prospective study. Patients with severe osteoarthritis of the knee, a psychiatric disorder, history of previous arthroplasty, bilateral osteoarthritis, contraindications to a major surgery, or failure to attend follow-up were excluded. The Harris Hip Score (HHS) was used to measure physical hip performance, ranging from 0 (poor) to 100

(excellent) points. All patients were followed for six months. Data were collected and analysed using SPSS with t-test analysis.

Results: A total of 58 patients were finally assessed, of whom 24 (41.4%) were male and others were female. The mean age was 56.8±16.56 years. The postoperative complications included infection (one case), posterior hip dislocation (two cases) and peroneal nerve paresis (one case). The mean HHS was 49.69±5 before the surgery, but it improved significantly to 88.02±4.04 at sixth months after THA ($p<0.001$).

Conclusion: According to this audit, THA is associated with a significant improvement and satisfactory outcome in the patients and the rate of complications was low.

Keywords: Harris Hip Score, Orthopedics, Osteoarthritis

INTRODUCTION

THA is an effective method for patients in the final stages of osteoarthritis. It can reduce the pain, increase the patients' ability to walk and recover their functions [1]. THA is one of the most common orthopedic surgeries [2], and is widely performed in the world (more than 1 million cases each year) [3]. Pain and dysfunction result from degenerative changes in the hip joint are the most frequent causes of THA [4,5]. Other indications for the surgery can be trauma, hip dislocation, avascular necrosis of femoral neck, Rheumatoid Arthritis (RA), lupus, and so on [6,7]. According to previously published data, after three to six months of THA, pain decreases and range of motion improves [8,9].

THA procedure can be associated with a series of complications, such as infection, hip and knee pain, hematoma in the surgical site, ectopic ossification, thromboemboli, limb-length discrepancies, prosthetic dislocation, and osteolysis [10,11]. These complications are divided into three categories: 1) complications related to surgery in the operating room; 2) short-term complications after surgery; 3) delayed complications after surgery.

There are not enough studies which directly evaluate complications and outcomes of THA. The purpose of the present study was mainly to investigate the results of THA in patents referred to the hospitals in Babol, north of Iran. Our results would be helpful for the clinicians to better find out the positive and negative points of THA procedure and select a good choice for treatment of the patients.

MATERIALS AND METHODS

Study population: This prospective study was performed on patients who referred to Shahid Beheshti and Ayatollah Rohani teaching hospitals to undergo THA during 2014-2015. Patients with severe knee osteoarthritis, a psychiatric disorder, history of previous arthroplasty, bilateral osteoarthritis, contraindications to a large surgery, and failure to follow-up, were excluded.

Data collection: The following information were collected from the patients: age, sex, height, weight, occupation, family history,

smoking history, underlying disease (including arthritis of the hip, diabetes, osteoporosis, etc.), history of hip fracture, type of fracture, surgical approach (posterior), complications after surgery (early loosening, dislocation, wear, infection, nerve damage).

Patients were evaluated in third and sixth weeks, and at third and sixth months after surgery. To measure physical hip performance, HHS was used. HHS is a scale to evaluate pain, patient's function during various activities, the deformity level and hip range of motion. Scoring range of 90-100 is excellent, 80-89 is good, 70-79 is average, and below 70 is poor [12].

Preoperative protocol: The procedure of the surgery and follow-up was stated to the patients. They were reassured about the surgical care, pain control and postoperative analgesia, and home discharge as soon as possible after the surgery. Appropriate antibiotic prophylaxis (Keflin 500 mg intravenously every 6 hours) was administered to all patients preoperatively.

Procedure of surgery: All patients underwent THA by the same surgeon. The surgeries were performed through the posterolateral approach. The procedures last between 45 and 90 minutes. All implants had a standard cementless cup and a cementless stem.

Postoperative protocol: Prophylaxis for thromboembolism (enoxaparin 4000 IU) was administered to all patients until they were able to walk independently. Then, enoxaparin was replaced by aspirin (80 to 160 mg per day). Blood transfusion was provided when needed. Two days after the surgery, the patients were encouraged to begin walking (by walker or cane) and physiotherapy was initiated. They also received the activities of daily living retraining.

STATISTICAL ANALYSIS

Collected data were analysed by SPSS software version 17.0. They underwent descriptive analysis. Also, t-test analysis was used to compare the HHS between different categories. A p-value less than 0.05 were considered statistically significant.

Ethical issues: This study was approved by ethical committee of Babol University of Medical Sciences and Health Services with code

of MUBABOL.REC.1393.13. The study procedure was explained to all patients before surgery and the informed consent was obtained from all of them.

RESULTS

A total of 58 patients were enrolled in this study, of whom 24 patients (41.4%) were male and 34 patients (58.6%) were female. The average age was 56.8±16.56-year-old. Salient patients' characteristics are shown in [Table/Fig-1].

Variable	N (%)
Gender	
Male	24 (41.4)
Female	34 (58.6)
Age (Mean±SD (year))	56.8±16.56
Smoking	
Yes	3 (5.2)
No	55 (94.8)
Opium intake	
Yes	6 (10.3)
No	52 (89.7)
Rheumatoid arthritis	
Yes	8 (13.8)
No	50 (86.2)
Diabetes mellitus	
Yes	4 (6.9)
No	54 (93.1)

[Table/Fig-1]: Salient characteristics of the patients.

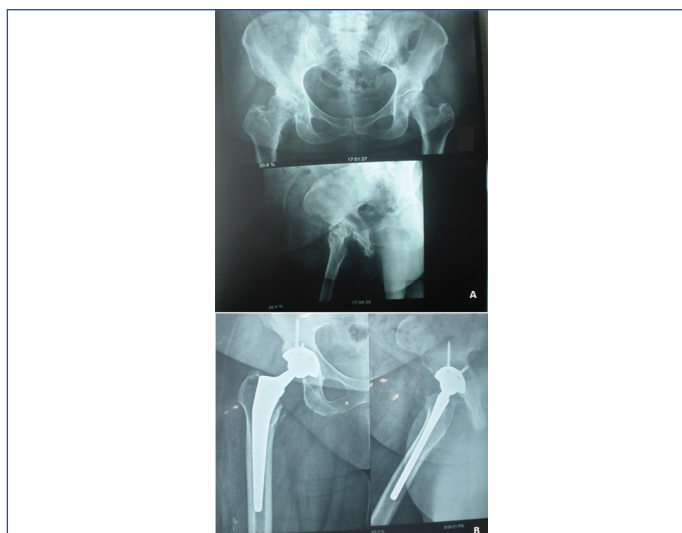
The indications for surgery were as follows: femoral head avascular necrosis, n=20 (34.5%); developmental dislocation of the hip, n=17 (29.3%); degenerative joint disease, n=16 (27.6%); femuro-acetabular impingement, n=5 (8.6%).

Regarding complications of THA, postoperative infection was seen only in one male patient which occurred ten days after the surgery. The complication was resolved by seven days antibiotic therapy. Two patients (one male and one female) over 70 years of age had postoperative posterior dislocation three months after the surgery which were reduced in the operating room. One diabetic male patient aged 78 years suffered from peroneal nerve paresis who was cured after three months. Thromboemboli was not observed in any case.

The HHS in patients at different times is presented in [Table/Fig-2]. As demonstrated, although mean HHS decreased during the first three weeks, after that, it was associated with an increase in the amount over time. The mean HHS before surgery was 49.69±5.00 and it progressed to 88.02±4.04 after 24 weeks (p<0.001). [Table/Fig-3] shows good outcome for a female patient, who was first presented with disruptive osteoarthritis of right femoral head, six months after the surgery. The patient was able to walk well and without lagging, and do all the necessary routine work with no pain and limitation.

Time of Evaluation	Harris Hip Score	
	Mean	Low Level-High Level
Before Surgery	49.69±5.00	48.37-51
3 rd week	42.77±5.66	41.28-44.26
6 th week	70.36±6.05	68.76-71.95
12 th week	76.56±4.39	77.41-79.73
24 th week	88.02±4.04	87.05-89.18

[Table/Fig-2]: The Harris Hip Score in patients before and after total hip arthroplasty in the third, sixth, twelfth and twenty-fourth weeks.



[Table/Fig-3]: (a) Patient with disruptive osteoarthritis of right femoral head before total hip arthroplasty; (b) After six months, the femoral and acetabular components were stable.

We tried to investigate the association between HHS and diseases of RA and diabetes mellitus in different times. In this regard, no significant differences were found in HHS between the groups with and without these two diseases [Table/Fig-4,5].

Time of Evaluation	Harris Hip Score		p-value
	RA* subjects (Mean±SD)	Non-RA subjects (Mean±SD)	
Before Surgery	47.87±2.29	49.98±5.27	0.27
3 rd week	41.62±3.11	42.96±5.97	0.35
6 th week	72.25±6.04	70.06±6.06	0.34
12 th week	79.62±4.98	78.40±4.32	0.46
24 th week	88.12±4.58	88.12±4.00	0.99

[Table/Fig-4]: Comparison of Harris Hip score between Rheumatoid Arthritis (RA) patients and non-rheumatoid arthritis patients.

* Rheumatoid arthritis

Time of Evaluation	Harris Hip Score		p-value
	Diabetic subjects (Mean±SD)	Non-diabetic subjects (Mean±SD)	
Before Surgery	47.50±6.02	49.85±4.95	0.36
3 rd week	41.00±6.37	42.90±5.65	0.52
6 th week	70.00±2.16	70.38±6.25	0.90
12 th week	76.75±4.57	78.70±4.39	0.39
24 th week	84.50±5.91	88.38±3.81	0.06

[Table/Fig-5]: Comparison of Harris Hip score between diabetic patients and non-diabetic patients.

DISCUSSION

In the present study, we assessed the outcome of the patients who underwent THA. As observed, HHS of the cases reached from 49.7 before the surgery to 88 six months after THA, indicating a satisfactory result. Study by Sachde B et al., indicated that preoperative mean HHS in the patients underwent THA was 49.1, and after four years, it reached to 89.9 and the patients were fully satisfied with their surgery [13]. Gross AE et al., also stated that THA could result in improvement of quality of patients' lives [14]. Besides, a long-term study on the patients aged <30-year-old showed high rate of survival (>90%), concluding that long-terms outcomes of THA in young patients are similar with those in older patients [15]. In a study by Sharma et al., who compared the outcomes of hemiarthroplasty and THA, the mean HHS in THA group was significantly more than hemiarthroplasty group (90 vs. 80) [16]. Such good outcomes were achieved in other surveys too [17-20], emphasizing the usefulness of THA for the patients' health recovery.

In our study, no significant differences were seen in the mean HHSs between RA and non-RA patients in different times. In their article, Schnaser EA et al., declared that RA and other inflammatory diseases could affect the status of the patients' recovery after surgery [21]. On the other hand, reduced rate of postoperative complications were identified in the RA patients versus osteoarthritis patients despite more comorbidities seen in the RA patients. In a study, it was revealed that cases with RA underwent primary THA have a similar survival compared with osteoarthritis patients [22]. Another survey also showed that THA can be a good choice for RA patients who are candidate for the surgery [23]. These reports are in agreement with our results, suggesting that there are probably no limitations for THA in RA patients. However, more studies are necessary to confirm this issue.

Diabetic patients who underwent THA had non-significant higher HHS than non-diabetic ones. In a previous study, HHS does not differ between diabetic and non-diabetic patients, although diabetic subjects may have a higher risk of infection [24]. On the other hand, some researchers explained that the outcomes of the diabetic patients is controversial [25]. This can be caused by factors, such as duration of diabetes, how to control it, and other underlying diseases. Therefore, additional surveys are needed to be done in order to find out the relation between THA outcome and diabetes.

Complications seen postoperatively in our study included infection (one case), neural damage (one case) and posterior dislocation (two cases). In Trojani C et al., study, it was reported that deep vein thrombosis and pulmonary emboli were the most common postoperative complications [26]. Besides, Schairer WW et al., documented that rate of complications differ in various times after surgery [27]. They also stated that the infection mostly occurs in the first three month. One of the complications is infection which can cause a lot of problems for the patient. Therefore, surgeon and patient should both attempt to prevent the incidence of infection in the surgery site. Also, all infections must be treated prior to the surgery. Another potential complication is dislocation, seen more frequently in the cases underwent the surgery because of fractures, and/or in the subjects who have pelvic muscle weakness [28,29]. Differences in postoperative complications depend on many factors, such as surgical facilities, skill and experience of the surgeon, patient's underlying diseases, his/her compliance to medical care instructions, and so on.

LIMITATION

One of the limitations that should be mentioned was that our study period was not so long enough that long-term postoperative complications could be investigated. Also, it is suggested that further studies to be performed with larger sample size.

CONCLUSION

THA had satisfactory outcomes for the patients of osteoarthritis and incidence of complications was not significant. These findings support the fact that THA is an appropriate choice for treatment.

ACKNOWLEDGEMENTS

The authors would like to thank Dr. Masoud Bahrami, Dr. Mani Falsafi and Dr. Rahmatollah Jokar for their advising on the study. Also, we thank Ms. Sekineh Kamali Ahangar for her help in preparing the manuscript.

REFERENCES

- [1] Isaacson MJ, Bunn KJ, Noble PC, Ismaili SK, Incavo SJ. Quantifying and Predicting Surgeon Work Input in Primary vs Revision Total Hip Arthroplasty. *J Arthroplasty*. 2016;31(6):1188-93.
- [2] Restrepo C, Parvizi J, Pour AE, Hozack WJ. Prospective randomized study of two surgical approaches for total hip arthroplasty. *J Arthroplasty*. 2010;25(5):671-9. e1.
- [3] Burge AJ. Total hip arthroplasty: MR imaging of complications unrelated to metal wear. *Semin Musculoskelet Radiol*. 2015;19(1):31-39.
- [4] Philippon M, Briggs K, Yen Y-M, Koppersmith D. Outcomes following hip arthroscopy for femoroacetabular impingement with associated chondrolabral dysfunction. *J Bone Joint Surg Br*. 2009;91(1):16-23.
- [5] Prudhon J-L, Desmarchelier R, Hamadouche M, Delaunay C, Verdier R. Causes for revision of dual-mobility and standard primary total hip arthroplasty. *Int Orthop*. 2017;41(3):455-59.
- [6] Parvizi J, Sullivan T, Duffy G, Cabanela ME. Fifteen-year clinical survivorship of Harris-Galante total hip arthroplasty. *J Arthroplasty*. 2004;19(6):672-77.
- [7] Dreinhöfer K, Dieppe P, Stürmer T, Gröber-Grätz D, Flören M, Günther K, et al. Indications for total hip replacement: comparison of assessments of orthopaedic surgeons and referring physicians. *Ann Rheum Dis*. 2006;65(10):1346-50.
- [8] Jones CA, Beaupre LA, Johnston D, Suarez-Almazor ME. Total joint arthroplasties: current concepts of patient outcomes after surgery. *Clin Geriatr Med*. 2005;33(1):71-86, vi.
- [9] Clair SFS, Higuera C, Krebs V, Tadross NA, Dumpe J, Barsoum WK. Hip and knee arthroplasty in the geriatric population. *Clin Geriatr Med*. 2006;22(3):515-33.
- [10] SooHoo NF, Farrag E, Lieberman JR, Chambers L, Zingmond DS. Factors that predict short-term complication rates after total hip arthroplasty. *Clin Orthop Relat Res*. 2010;468(9):2363-71.
- [11] Bozic KJ, Ong K, Lau E, Kurtz SM, Vail TP, Rubash HE, et al. Risk of complication and revision total hip arthroplasty among Medicare patients with different bearing surfaces. *Clin Orthop Relat Res*. 2010;468(9):2357-62.
- [12] Singh JA, Schleck C, Harmsen S, Lewallen D. Clinically important improvement thresholds for Harris Hip Score and its ability to predict revision risk after primary total hip arthroplasty. *BMC Musculoskelet Disord*. 2016;17:256.
- [13] Sachde B, Maru ND. Mid-term results of large diameter heads of cross-linked polyethylene liners in total hip replacement. *J Clin Orthop Trauma*. 2012;3(2):94-97.
- [14] Gross AE, Callaghan JJ, Zywiol MG, Greiner JJ, Kosashvili Y, Johnson AJ, et al. Total hip arthroplasty in Down syndrome patients: an improvement in quality of life: replacement arthroplasty in Down syndrome (RADS) study group. *J Arthroplasty*. 2013;28(4):701-06.
- [15] Pakos EE, Paschos NK, Xenakis TA. Long term outcomes of total hip arthroplasty in young patients under 30. *Arch Bone Jt Surg*. 2014;2(3):157-62.
- [16] Sharma V, Awasthi B, Kumar K, Kohli N, Katoch P. Outcome analysis of hemiarthroplasty vs. total hip replacement in displaced femoral neck fractures in the elderly. *J Clin Diagn Res*. 2016;10(5):RC11-13.
- [17] Woo MS, Kang JS, Moon KH. Outcome of total hip arthroplasty for avascular necrosis of the femoral head in systemic lupus erythematosus. *J Arthroplasty*. 2014;29(12):2267-70.
- [18] Lin S, Zhang C-q, Jin D-x. Combination of modified free vascularized fibular grafting and reverse Less Invasive Stabilization System (LISS) for the management of femoral neck nonunion in patients thirty years of age or younger. *Injury*. 2015;46(8):1551-56.
- [19] Yuan B, Taunton MJ, Trousdale RT. Total hip arthroplasty for alcoholic osteonecrosis of the femoral head. *Orthopedics*. 2009;32(6):400.
- [20] Kiran Kumar G, Meena S, Kumar V, Manjunath S, MK VR. Bipolar hemiarthroplasty in unstable intertrochanteric fractures in elderly: a prospective study. *J Clin Diagn Res*. 2013;7(8):1669-71.
- [21] Schnaser EA, Browne JA, Padgett DE, Figgie MP, D'Apuzzo MR. Perioperative complications in patients with inflammatory arthropathy undergoing total knee arthroplasty. *J Arthroplasty*. 2015;30(9):76-80.
- [22] Rud-Sørensen C, Pedersen AB, Johnsen SP, Riis AH, Overgaard S. Survival of primary total hip arthroplasty in rheumatoid arthritis patients: findings in 1,661 arthroplasties in 1,395 patients from the Danish Hip Arthroplasty Registry. *Acta orthopaedica*. 2010;81(1):60-65.
- [23] Ito H, Tanino H, Yamanaka Y, Minami A, Matsuno T. Intermediate-to long-term results after hybrid total hip arthroplasty in patients with rheumatoid arthritis. *J Arthroplasty*. 2013;28(2):309-14.
- [24] Malinzak RA, Ritter MA, Berend ME, Meding JB, Olberding EM, Davis KE. Morbidly obese, diabetic, younger, and unilateral joint arthroplasty patients have elevated total joint arthroplasty infection rates. *J Arthroplasty*. 2009;24(6):84-88.
- [25] Bolognesi MP, Marchant MH, Viens NA, Cook C, Pietrobon R, Vail TP. The impact of diabetes on perioperative patient outcomes after total hip and total knee arthroplasty in the United States. *J Arthroplasty*. 2008;23(6):92-98.
- [26] Trojani C, d'Ollonne T, Saragaglia D, Vielpeau C, Carles M, Prudhon J-L. One-stage bilateral total hip arthroplasty: functional outcomes and complications in 112 patients. *Orthop Traumatol Surg Res*. 2012;98(6):S120-S3.

- [27] Schairer WW, Nwachukwu BU, Mayman DJ, Lyman S, Jerabek SA. Preoperative hip injections increase the rate of periprosthetic infection after total hip arthroplasty. *J Arthroplasty*. 2016;31(9):166-9. e1.
- [28] Soong M, Rubash HE, Macaulay W. Dislocation after total hip arthroplasty. *J Am Acad Orthop Surg*. 2004;12(5):314-21.
- [29] Kim Y, Kim JK, Joo IH, Hwang KT, Kim YH. Risk factors associated with dislocation after bipolar hemiarthroplasty in elderly patients with femoral neck fracture. *Hip Pelvis*. 2016;28(2):104-11.

PARTICULARS OF CONTRIBUTORS:

1. Postgraduate Student, Student Research Committee, School of Medicine, Babol University of Medical Sciences, Babol, Mazandaran, Iran.
2. Professor, Health Research Institute, Babol University of Medical Sciences, Babol, Mazandaran, Iran.
3. Associate Professor, Orthopedic Research Center, Mazandaran University of Medical Sciences, Sari, Mazandaran, Iran.
4. Associate Professor, Department of Orthopedics, Mazandaran University of Medical Sciences, Sari, Mazandaran, Iran.
5. Associate Professor, Clinical Research Development Center, Babol University of Medical Sciences, Babol, Mazandaran, Iran.
6. Medical Student, Student Research Committee, School of Medicine, Babol University of Medical Sciences, Babol, Mazandaran, Iran.

NAME, ADDRESS, E-MAIL ID OF THE CORRESPONDING AUTHOR:

Dr. Seyed Mokhtar Esmailnezhad Ganji,
Associate Professor, Department of Orthopedics, Babol University of Medical Sciences, Ganjafrooz Street,
Babol, Mazandaran, Iran.
E-mail: smsnganji@yahoo.com

Date of Submission: **Jan 24, 2018**Date of Peer Review: **Mar 19, 2018**Date of Acceptance: **Apr 05, 2018**Date of Publishing: **Jul 01, 2018****FINANCIAL OR OTHER COMPETING INTERESTS:** None.